

Post-Cardiotomy Shock Following Double-Valve Surgery Secondary to *Enterococcus durans* Endocarditis: Case Report and Comprehensive Literature Review

Ravi Korabathina¹, Sophia Ciaravino, Steven V Curiale and Hugh M van Gelder

¹ Department of Cardiology, University of South Florida Morsani College of Medicine, Tampa, FL, USA

² Department of Family Practice, Bayfront Medical Center, St. Petersburg, FL, USA

³ Department of Cardiothoracic Surgery, Bayfront Medical Center, St. Petersburg, FL, USA

*Corresponding author: Ravi Korabathina, Assistant Professor of Medicine, Department of Cardiology, University of South Florida Morsani College of Medicine, Tampa, FL, USA Tel: 917-309-5114; E-mail: r_korabathina@yahoo.com

Received Date: Nov 18, 2019; Accepted Date: Nov 29, 2019; Published Date: Dec 06, 2019

Copyright: © 2019 Korabathina R, et al. This is an open-access article distributed under the terms of the Creative Commons Attribution License, which permits unrestricted use, distribution, and reproduction in any medium, provided the original author and source are credited.

Abstract

Bacterial endocarditis resulting from *Enterococcus durans* is rarely reported, but when present is generally associated with favorable prognosis. We present the first report of a young male without pre-existing cardiac conditions who developed respiratory failure and hemodynamic instability related to double valve *E. durans* endocarditis. Following emergent valve surgery, he developed post-cardiotomy shock that was successfully bridged to recovery using extracorporeal membranous oxygenation therapy. We describe the exhaustive post-operative work-up to identify the etiology for post-cardiotomy shock, and speculate that the patient developed sepsis-related cardiomyopathy immediately following surgery with new marked depression in left ventricular contractility that completely normalized with left ventricular support. After comprehensive literature review consisting of only seven other reports of *E. durans* endocarditis, this report questions the previously held notions regarding the low-virulence characteristics of this particular Enterococcal species. Furthermore, in scenarios where salvage therapy for post-cardiotomy shock becomes necessary following emergent valve surgery for bacterial endocarditis, the importance of having access to left ventricular assist devices is emphasized.

Keywords: Surgical pathology; Infective Endocarditis; Lactococcus bacteremia; cardiomyopathy

Introduction

Enterococcus durans endocarditis is exceedingly rare but seemingly treatable with favorable prognosis. We report a unique case of a young patient who developed double-valve endocarditis and presented with cardiogenic shock due to this pathogen. Following emergent but successful valve surgery, he then developed post-cardiotomy shock that was successfully bridged to recovery using a left ventricular assist device. No such case with *E. durans* has been previously reported.

Case Report

The patient is a 41 year old African American male with a history of malignant hypertension, end stage renal disease, and treated bacteremia for a Lactococcus species two months prior who presented with severe chest discomfort and respiratory failure necessitating mechanical ventilator support. Emergent cardiac catheterization revealed normal coronary arteries, but hemodynamics were consistent with shock (central aortic pressure 64/28 and pulse 104 beats per minute). Transient stabilization was achieved with intermediate doses of dopamine and norepinephrine. Urgent transthoracic and transesophageal echocardiography (TTE and TEE, respectively) revealed preserved biventricular systolic function but severe aortic valve and moderate mitral valve regurgitation with multiple aortic and mitral valve echodensities (Figure 1), that were not present during the prior TEE performed for Lactococcus bacteremia.

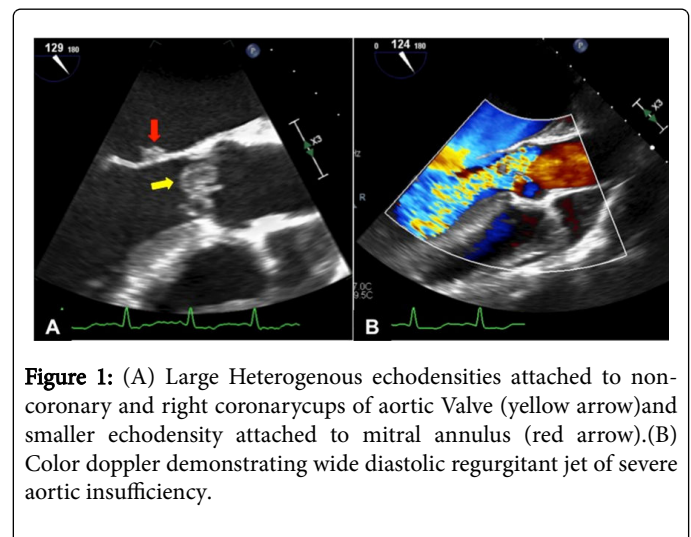


Figure 1: (A) Large Heterogenous echodensities attached to non-coronary and right coronary cups of aortic Valve (yellow arrow) and smaller echodensity attached to mitral annulus (red arrow). (B) Color doppler demonstrating wide diastolic regurgitant jet of severe aortic insufficiency.

The patient remained febrile, and physical examination was pertinent for a grade 3/6 systolic ejection murmur, grade 3/6 diastolic rumble, and cool extremities. Laboratory profile was remarkable for leukocytes 19.5/mL, hemoglobin 7.9 g/dL, serum creatinine 4.3 mg/dL, and lactate 10.4 mmol/L. After 72 hours, the two sets of blood cultures drawn at admission grew *Enterococcus durans* with antibiotic testing showing susceptibility to ampicillin and gentamycin, and so duration of antibiotic therapy was targeted at 6 weeks. The diagnosis was definite double valve infective endocarditis (IE).

Given heart failure with cardiogenic shock, emergent valve surgery was performed within 24 hours following initial diagnosis. The patient underwent standard bicaval cannulation with routine cardiopulmonary bypass. Intraoperative findings demonstrated large aggregates of vegetation involving all three destroyed aortic valve leaflets, and so a pericardial bioprosthesis was positioned following leaflet resection. The mitral valve also exhibited a vegetation with A1 and A2 anterior leaflet perforation, and so complex repair with a Cor matrix patch, Gortex neo-chords and ring annuloplasty was performed. The patient tolerated the procedure well and was easily separated from cardiopulmonary bypass with low dose norepinephrine. Post-operative TEE confirmed normal biventricular systolic function with optimal valve replacement/repair and no residual valve regurgitation or perivalvular leak. He was then transported to post-operative recovery. Surgical pathology revealed both acute and chronic inflammation with necrosis, and tissue cultures were eventually conclusive for *E. durans*.

Upon arrival to the recovery unit, the patient's hemodynamics deteriorated rapidly with profound hypoxia that was refractory to maximum escalation of three vasopressors and ventilator setting adjustments. The patient also developed cardiac arrest requiring advanced cardiopulmonary life support. Bronchoscopy verified appropriate endotracheal tube placement, and eventual computed tomography imaging of the thorax did not show any evidence of pulmonary embolism. Methemoglobinemia was ruled out, and the patient was given empiric methylene blue treatment. Pericardial tamponade was excluded and normal bioprosthetic valve function was confirmed by repeat TTE and TEE, but remarkably these studies showed newfound severe left ventricular systolic dysfunction with marked global hypokinesia. Given post-cardiotomy shock (PCS) and imminent death, the patient was emergently transitioned to peripheral venous-arterial extracorporeal membranous oxygenation (ECMO) to achieve hemodynamic stability. Over the next several days, the patient was maintained on continuous veno-venous hemodialysis and managed by multiple specialties. Within 72 hours of full

cardiopulmonary support, his heart failure improved with lessening vasopressor requirement and improvement in markers of end-organ perfusion, and repeat TTE demonstrated normalization of left ventricular systolic function. ECMO was successfully weaned and explanted after 6 days of hemodynamic support with maintenance of stable hemodynamics and without use of further vasopressors. Despite recovery from PCS and restoration of normal neurologic function, the patient faced a prolonged hospitalization, with multiple critical care issues including ECMO cannula-related limb ischemia requiring amputation, hematologic issues, and secondary sepsis that ultimately led to death at 62 days of hospitalization.

Discussion

Enterococcal bacteremia is commonly recognized in the nosocomial setting and associated with high in-hospital mortality rates [1]. Among Enterococcal species, *E. faecalis* and *E. faecium* are most prevalent, while other species such as *E. durans* are extremely rare. In fact, the largest nine-year, retrospective clinical survey of 3,017 Enterococcal isolates attributed only 2 cases (0.06%) to *E. durans* [2]. In terms of bacterial IE, Enterococcus is the causative microbe in 20 percent of all cases, but again the majority are due to *E. faecalis* and *E. faecium* [3,4]. As such, any experience with non-*faecalis*, non-*faecium* species leading to IE is extremely limited. An extensive PubMed search yielded only 7 previous cases of *E. durans* IE (Table 1), with survival noted in 5 reports.

Given that 6 out of 7 previous cases had predisposing cardiac conditions, this current report of E [5-11]. Durans IE is unique in describing the youngest subject to date without pre-existing valvular disease who developed the highest severity of illness with double-valve disease complicated by cardiogenic shock. Furthermore, this is the first case to illustrate the occurrence of PCS despite successful valve surgery that was bridged to recovery using ECMO. This case challenges previous notions regarding the low-virulence characteristics of this particular *Enterococcal* species.

Author (Country, Publication Date)	Age, Gender	Risk factors	Valve (s) Involved	Antibiotic Therapy	Surgery	Discharge
Tripodi, et al. (Italy 1998) [5]	74, Male	Prostatectomy	Native, mitral valve	Intravenous Ampicillin and Ciprofloxacin (both 6 weeks)	None	Alive
Stepanovic, et al. (Serbia, 2003) [6]	44, Male	Transposition of great vessels (untreated); DM; Refugee camp	Native, tricuspid valve	Intravenous Ampicillin (6 weeks) and Gentamicin (10 days)	None	Alive
Vijayakrishnan, et al. (United States, 2012) [7]	61, Male	Cirrhosis; Severe aortic valve stenosis	Native, aortic valve	Intravenous Ampicillin and Gentamicin (both 6 weeks)	None	Deceased
Kenzaka, et al. (Japan, 2013) [8]	83, Male	ESRD; DM; Moderate aortic valve stenosis	Native, aortic valve	Intravenous Ampicillin and Gentamicin (both 6 weeks)	None	Alive
Zala, et al. (Australia, 2016) [9]	61, Male	Bioprosthetic aortic valve replacement	Bioprosthetic, aortic valve	Intravenous Penicillin (6 weeks x2)	Aortic replacement valve	Alive
Fallavollita, et al. (Italy, 2016) [10]	74, Male	Bioprosthetic aortic valve; HTN	Bioprosthetic, aortic valve	Intravenous Teicoplanin and Gentamicin (both 6 weeks)	None	Alive

Sunbul, et al. (Turkey, 2017) [11]	71, Male	COPD; DM; Heart failure	Native, mitral valve	Intravenous Ciprofloxacin and Daptomycin (both 6 weeks)	Mitral valve replacement (after 35 days of antibiotic therapy)	Deceased
Current Report (United States, 2018)	41, Male	ESRD; HTN	Native, aortic and mitral valve	Intravenous Ampicillin and Gentamycin (both 6 weeks)	Aortic valve replacement; Mitral valve repair (after 2 days of antibiotic therapy)	Deceased

Table 1: Reported Cases of *Enterococcus durans* Endocarditis.

Post-cardiotomy shock occurs in approximately 1 percent of coronary and valve surgery cases and in spite of using salvage therapy with ECMO carries a dismal prognosis even in contemporary studies [12-14]. In the largest single center series of 517 PCS cases, 5 percent occurred following cardiac surgery that was performed for IE, and 80 percent of these patients died before hospital discharge [15]. Intuitively, coexistent heart failure with IE impacts surgical outcomes, and data from the largest, international registry of 4,075 IE patients demonstrated a near 3-fold higher mortality if heart failure were present [16]. Our patient represented an extreme on the heart failure spectrum with cardiogenic shock requiring mechanical ventilator support, already conferring him the highest surgical risk. Interestingly, despite hemodynamic improvement immediately following surgery, thus allowing for uneventful weaning from cardiopulmonary bypass, he rapidly progressed to develop PCS with refractory hypoxia and notable decline in left ventricular contractility. After a comprehensive but unrevealing search for potential reversible causes, we felt that the most likely mechanism for PCS was the large release of bacterial toxins and pro-inflammatory mediators from the underlying infectious source that hitherto received minimal antibiotic treatment. Speculatively, there was a transition from cardiogenic shock to septic shock related to *E. durans*. The role of sepsis in eliciting cardiomyopathy is recognized [17].

Conclusion

Our case demonstrates the successful use of ECMO to bridge a critically ill IE PCS patient to recovery with restoration of normal left ventricular contractility. In spite of tremendous resource use, the occurrence of ECMO-related limb ischemia, secondary sepsis, and progressive multi-organ failure prolonged his hospital stay and ultimately led to death. Cardiovascular and infectious disease clinicians must become fully aware of the potential catastrophic complications that could arise following emergent surgery for IE. Particularly in cases of shock presentation, ventricular assist devices should be readily available if salvage therapy becomes necessary.

References

- McDonald JR, Olaison L, Anderson DJ, Hoen B, Miro JM, et al. (2005) Enterococcal endocarditis: 107 cases from the international collaboration on endocarditis merged database. Am J Med 118: 759-766.
- Tan CK, Lai CC, Wang JY, Lin SH, Liao CH, et al. (2010) Bacteremia caused by non-faecalis and non-faecium enterococcus species at a Medical center in Taiwan, 2000 to 2008. J infect 61: 34-43.
- Madsen KT, Skov MN, Gill S, Kemp M. (2017) Virulence Factors Associated with *Enterococcus Faecalis* Infective Endocarditis: A Mini Review. open microbiol J 11: 1-11.
- Murdoch DR, Corey GR, Hoen B, Miro JM, Bayer AS, et al. (2009) Clinical presentation, etiology, and outcome of infective endocarditis in the 21st century: the International Collaboration on Endocarditis-Prospective Cohort Study. Arch Intern Med 169: 463-73.
- Tripodi MF, Locatelli A, Adinolfi LE, Andreana A, Utili R. (1998) Successful treatment with ampicillin and fluoroquinolones of human endocarditis due to high-level gentamicin-resistant enterococci. Eur J Clin Microbiol Infect Dis 17: 734-736.
- Stepanovic S, Jovanovic M, Lavadinovic L, Stosovic B, Pelemis M. (2004) *Enterococcus durans* endocarditis in a patient with transposition of the great vessels. J Med Microbiol 53: 259-261.
- Vijaykrishnan R, Rapose A. (2012) Fatal *Enterococcus durans* aortic valve endocarditis: a case report and review of the literature. BMJ Case Rep 2012.
- Kenzaka T, Takamura N, Kumabe A, Takeda K (2013) A case of subacute infective endocarditis and blood access infection caused by *Enterococcus durans*. BMC Infect Dis 13: 594.
- Zala A, Collins N (2016) *Enterococcus durans* Prosthetic Valve Endocarditis: A Previously Unreported Clinical Entity. Heart Lung Circ 25: 133-136.
- Fallavollita L, Di Gioacchino L, Balestrini F (2016) Bioprosthetic Aortic Valve Endocarditis in Association with *Enterococcus durans*. Tex Heart Inst J 43: 165-167.
- Sunbul M, Cerik HO, Cerik B, Gulel O, Leblebicioglu H (2017) *Enterococcus durans* Endocarditis. Ame J Ther 25: 663-665.
- Sakata R, Fujii Y, Kuwano H. (2011) Thoracic and cardiovascular surgery in Japan during 2009: annual report by the Japanese Association for Thoracic Surgery. Gen Thorac Cardiovasc Surg 59: 636-667.
- McCarthy FH, McDermott KM, Kini V (2015) Trends in U.S. Extracorporeal Membrane Oxygenation Use and Outcomes: 2002-2012. Semin Thorac Cardiovasc Surg 27: 81-88.
- Raffa GM, Kowalewski M, Brodie D, Ogino M, Whitman M, et al. (2018) Meta-Analysis of Peripheral or Central ECMO in Postcardiotomy and Non-Postcardiotomy Shock. Ann Thorac Surg 107: 311-321.
- Rastan AJ, Dege A, Mohr M, Doll N, Falk Vet al. (2010) Early and late outcomes of 517 consecutive adult patients treated with extracorporeal membrane oxygenation for refractory postcardiotomy cardiogenic shock. J Thorac Cardiovasc Surg 139: 302-311.
- Kiefer T, Park L, Tribouilloy C, Cortes C, Casillo R, et al. (2011) Association between valvular surgery and mortality among patients with infective endocarditis complicated by heart failure. JAMA 306: 2239-2247.
- Muller-Werdan U, Prondzinsky R, Werdan K (2016) Effect of inflammatory mediators on cardiovascular function. Curr Opin Crit Care 22: 453-463.