

# Prolonged Infusional Chemotherapy in Colon Cancer

Agnello Russo\*,

Oncologist; Via Bagnulo n°33, Piano di Sorrento (NA), 80063 Italy

## Corresponding Author\*

Agnello Russo

Oncologist; Via Bagnulo, n°33, Piano di Sorrento (NA)

80063, Italy

E-mail: [drnellorusso@gmail.com](mailto:drnellorusso@gmail.com)

**Copyright:** ©2023 Russo, A This is an open-access article distributed under the terms of the Creative Commons Attribution License CC-BY, which permits unrestricted use, distribution, and reproduction in any medium, provided the original author and source are credited.

**Received:** 10 Feb 2023, Manuscript No. OCCRS-23-89213; **Editor assigned:** 16 Feb 2023, PreQC No OCCRS-23-89213 (PQ); **Reviewed:** 17 Feb 2023, QC No. OCCRS-23-89213 (Q); **Revised:** 20 Feb 2023, Manuscript No. OCCRS-23-89213 (R); **Published:** 30 Mar 2023. **doi:** 10.35248/23.9.2.1-2

## Abstract

This case is the presentation of complete and definitive disappearance of a liver metastasis in colon cancer of a woman of 77 years old, with a long time chemotherapy.

**Keywords:** Turnover time • Colon • Cellular kinetic

## Introduction

Primary peritoneal carcinoma is a rare intra-abdominal carcinomatosis, Colon and rectum cancer are among the most common cancers with increase of incidence. Unfortunately a lot of these patients will develop distant metastasis sometimes during the course of their illness. In this cancer is used a therapy following the turnover time and cellular kinetic [1-3]. The turnover time of the normal cells of the colon can change between 39 hours and 48 hours, in the cancerous cells is about 8 hours [4, 5]. Using a chemotherapy with low dose and continuous on a long time during all phases of the following mitosis there is the apoptosis of the cancer cells [6, 7].

## Materials and Methods

The administration is done with seven days' infuser 0,5 ml/hour with Fluorouracil (200 mg/sqm) a day for seven days. Folinic acid left handed form (175 mg) in bolus every seven days. This therapy is administered for three times in succession. After three weeks of infusion Oxaliplatin (dose 80 mg/sqm in 250 ml of glucose 5%) is administered. The period of suspension is 21 days/28 days but may be longer until the patient is in good conditions. Before starting every cycle leukocyte, platelets, liver, kidney and cardiac functions are evaluated.

## Case Presentation

A woman of 77 years old with sigma's adenocarcinoma. First step surgery was performed with the left hemicolectomy PET 5/5/2009 liver metastasis 4 segment (suv 4,00), ultrasonography: liver 6/7/2009 hyperechoic area 15 mm faded edges margins vascular signal positive at power doppler. The patient started chemotherapy with infusion for five cycles of three weeks. Disappearance of liver metastasis in ultrasonography of April 2010 and TAC of October 2010. The follow up is negative not reappeared of liver metastasis in the life of the patient.

## Discussion

The chemotherapy intravenous on a long time with administration of low doses hit cells of cancer thought all the phases of cellular cycles and for more consecutive cell cycles with a decrease of toxicity of drugs [8, 9]. It is so possible to give the drugs during the hours most biologically favorable to kill neoplastic cells [10, 11]. With this method, three liver metastasis with 3 cm of diameter can be definitively destroyed, in neoadjuvant chemotherapy of transverse colon with two cycles. I had complete disappearance of primitive neoplastic ulcer, in colon descending mucinous adenocarcinoma with peritoneal ascites. I had complete disappearance of the ascites and the patient survived 8 years after the diagnosis (Figures 1-5).

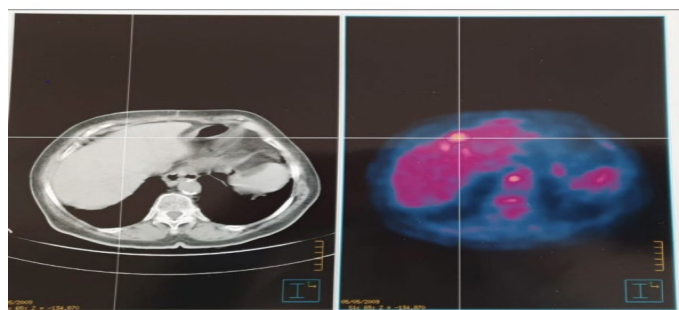


Figure 1. Computed tomography scan of liver metastasis.

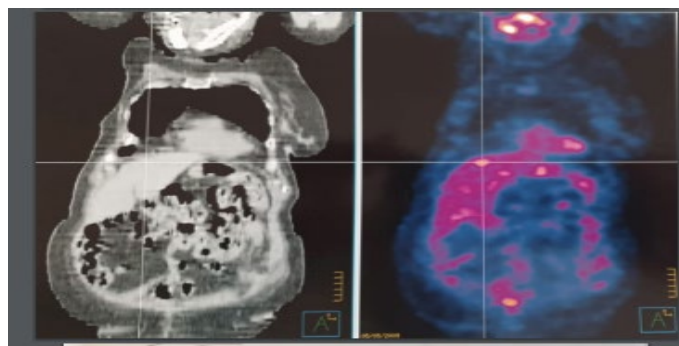


Figure 2. Left hemicolectomy PET 5/5/2009 liver metastasis 4 segment.

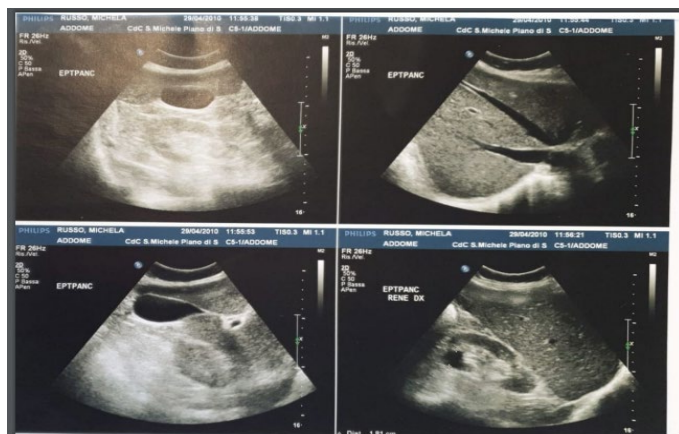

Figure 3. Ultrasound of Liver after chemotherapy without the metastasis

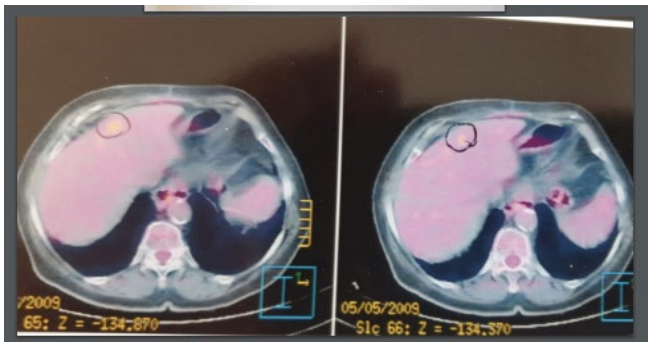


Figure 4. CT scan of liver metastasis.

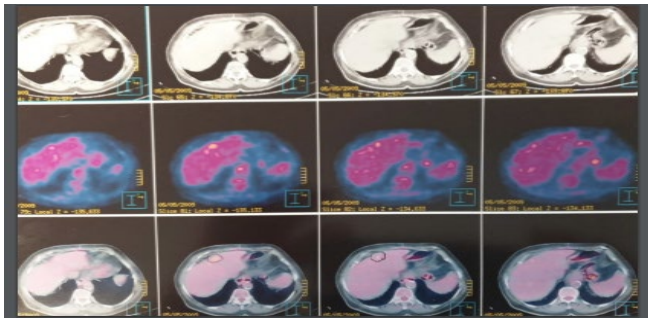


Figure 5. Axial images of a patient with liver cancer.

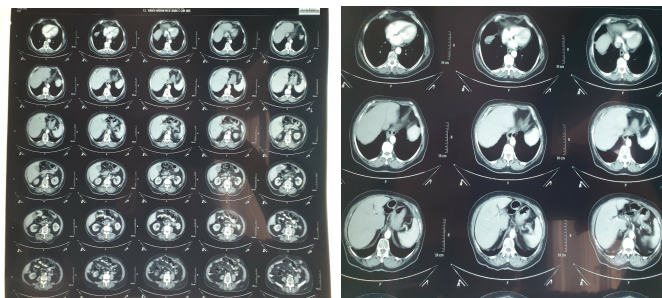


Figure 6. Computerized axial tomography of liver on 22/10/2010

## Conclusion

This therapy shows better results other than standard chemotherapy.

## References

1. Kemeny, N., et al. "Hepatic arterial infusion of chemotherapy after resection of hepatic metastases from colorectal cancer." *N Engl J Med.* 341.27 (1999): 2039-2048.
2. Goldberg, R.M., et al. "A randomized controlled trial of fluorouracil plus leucovorin, irinotecan, and oxaliplatin combinations in patients with previously untreated metastatic colorectal cancer." *J Clin Oncol.* 22.1 (2004): 23-30.

3. Tournigand, C, et al. "FOLFIRI followed by FOLFOX6 or the reverse sequence in advanced colorectal cancer: a randomized GERCOR study." *J. Clin Oncol.* 22.2 (2004): 229-237.
4. André, T., et al. "Pembrolizumab in microsatellite-instability-high advanced colorectal cancer." *N. Engl. J. Med.* 383.23 (2020): 2207-2218..
5. Yuan, C., et al. "Plasma 25-Hydroxyvitamin D Levels and Survival in Patients with Advanced or Metastatic Colorectal Cancer: Findings from CALGB/SWOG 80405 (Alliance) Vitamin D and Advanced/Metastatic Colorectal Cancer Survival." *Clin Cancer Res.* 25.24 (2019): 7497-7505..
6. Triolo, V.A., & Shimkin, M.B. "The American Cancer Society and cancer research origins and organization: 1913-1943." *Cancer res.* 29.9 (1969): 1615-1641.
7. Johns, L.E., & Houlston, R.S.. "A systematic review and meta-analysis of familial colorectal cancer risk." *Am. j. gastroenterol.* 96.10 (2001): 2992-3003.
8. Imperiale, T.F., et al. "A risk index for advanced neoplasia on the second surveillance colonoscopy in patients with previous adenomatous polyps." *Gastrointest. endosc.* 80.3 (2014): 471-478..
9. Singh, H., et al. "Risk of colorectal cancer after diagnosis of endometrial cancer: a population-based study." *J Clin Oncol* 31.16 (2013): 2010-2015.
10. Srinivasan, R., et al. "Risk of colorectal cancer in women with a prior diagnosis of gynecologic malignancy." *J. clin. gastroenterol.* 41.3 (2007): 291-296..
11. Francis, L. et al. "Oxaliplatin activity against metastatic colorectal cancer. A phase II study of 5-day continuous venous infusion at circadian rhythm modulated rate." *Eur. J. Cancer* 29.9 (1993): 1280-1284..