

# Management of Trismus using a Mouth Gag with Expansion Screw and a Posterior Bite Plane: A Case Report

Shiro Kubo\*

Department of Oral Surgery, Kubo Dental Clinic, Wakkanai City, Hokkaido, Japan

## Corresponding Author\*

Dr. Shiro Kubo

Department of Oral Surgery, Kubo Dental Clinic,

Wakkanai City, Hokkaido

Japan

E-mail: kubo-shi@sage.ocn.ne.jp

**Copyright:** © 2021 Kubo S. This is an open-access article distributed under the terms of the Creative Commons Attribution License, which permits unrestricted use, distribution, and reproduction in any medium, provided the original author and source are credited.

**Received date:** 07 October, 2021; **Accepted date:** 21 October, 2021; **Published date:** 28 October, 2021

## Abstract

This report describes the conservative management of trismus caused by osteoarthritis of the Temporomandibular Joint (TMJ). Trismus was treated using a mouth gag with an expansion screw and a posterior bite plane for the lateral movement of the mandible. These two appliances were effective in increasing mouth opening and relieving TMJ pain.

**Keywords:** Trismus • Osteoarthritis of temporomandibular joint • Mouth gag • Bite plane

## Introduction

Trismus is frequently seen in clinical conditions, such as arthroses of the TMJ-1, and rheumatoid arthritis-2 and it is a prognostic symptom of the Condylar Process Fracture of Mandible (CPFJ). Osteoarthritis is the most common arthritis which affects the human body and can affect the TMJ.

A 76-year-old woman with trismus caused by Osteoarthritis of the TMJ, deformity of the condylar head, subchondral cysts and severe bony resorption of the articular fossa was treated using a mouth gag with an expansion screw and a posterior bite plane.

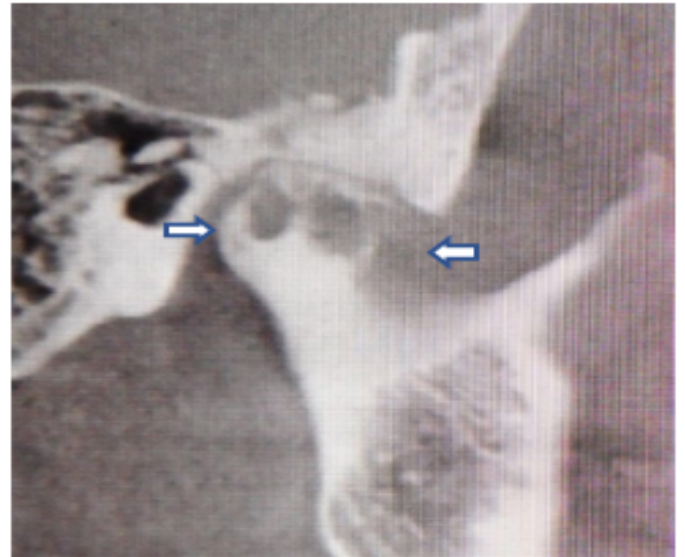
These appliances cause less damage to the teeth and TMJ than do other mouth gags. The main advantage of these appliances is the rigid fixation of the dental arch without any damage to the teeth and TMJ. This technique is advantageous because patients can easily practice by themselves at home [1].

## Case Report

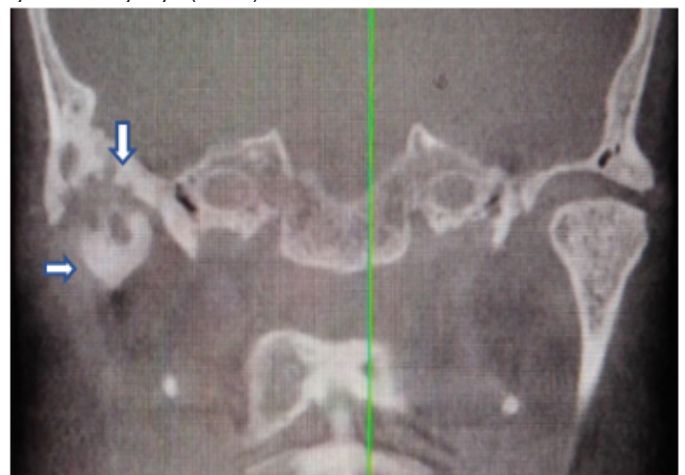A 76-year-old woman visited our dental clinic with trismus and pain in the right TMJ. At that time, she received an intra-articular steroid injection, but it had no effect. The maximum interincisal mouth opening distance was 17 mm. The orthopantomogram and Computed Tomography (CT) revealed severe two subchondral cysts called Ely's cyst in the right condylar head. The loss of joint space was remarkable (Figure 1).

The resorption of the articular fossa and condylar head were observed (Figure 2). On the right side, only slight rotation of the condylar head, without translation, was observed.

The rotation and translation of the left condylar head were normal. On orthopedic examination, a characteristic enlargement at the distal interphalangeal joint, called Heberden's node, was seen [2]. Laboratory studies were requested blood count, erythrocyte sedimentation rate, rheumatoid factor, and antinuclear antibodies. All these test results were in the normal range.



**Figure 1.** Sagittal CT of right TMJ: Loss of joint space and two subchondral cysts called Ely's cyst (arrows).



**Figure 2.** Coronal CT: Severe bone resorption of the articular fossa and condylar head (arrows).

## Treatment

The patient did not wish to undergo surgery for trismus. Physiotherapy was recommended, which included mouth opening using Heister's mouth gag-7. She complained that it was not admirably adapted to the dental arch and was anxious about fracture of the teeth [3]. Treatment using a mouth gag with an expansion screw 8 and a posterior bite plane for lateral movement of mandible was suggested (Figures 3 and 4). One month later, the maximal inter-incisal mouth opening distance improved from 17 mm to 36 mm. The lateral movement to the left side improved from 4 mm to 10 mm. Originally, the expansion screw is used to correct cross-bites, narrow arches, and crowding and the posterior bite plane is placed at an angle of 45 degrees to the occlusal plane, which are widely used in orthodontic treatment. In this case modified orthodontic appliances were adapted for the patient after obtaining informed consent [4].

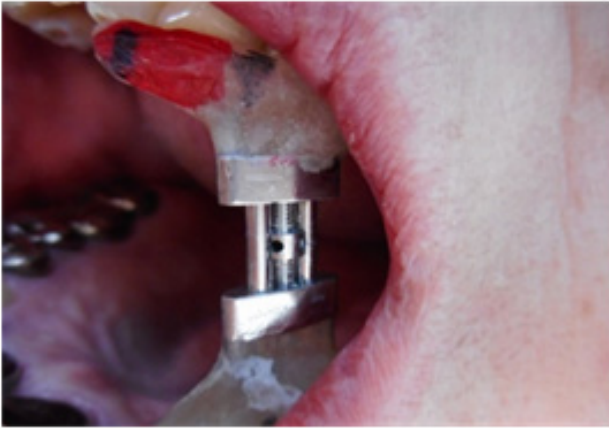

Figure 3. Mouth gag using expansion screw.

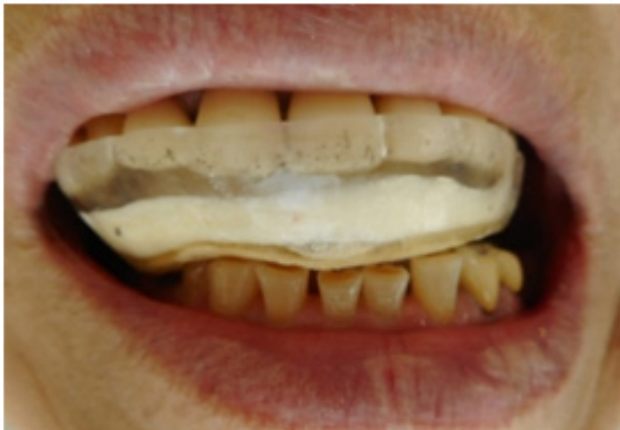

Figure 4. Inclined plane leads the mandible to the left (arrow).

## Discussion

Trismus refers to the inability to open the mouth and results from pathosis in various of structures. At the first medical examination, suspected rheumatoid arthritis was ruled out by orthopedic examination and blood tests. She was eventually diagnosed Heberden's node because of various tests. The two-small oval, radiolucent lesions were subchondral cysts called Ely's cysts. The patient had no history of CPM. She was informed about the surgical treatment. She wanted conservative treatment for trismus and pain control [5]. Therefore, the patient was advised to undergo physiotherapy using a mouth gag with an expansion screw and a posterior bite lane. The expansion screw does not damage the periodontal ligament or teeth like other mouth gags, such as the Ferguson, Heister, or Denhart mouth gags. The force was distributed equally to all teeth using

the expansion screw. This mouth gag is a remarkable improvement to those currently in use. Traditional mouth gags pose a risk of tooth fracture. Most gags tend to slip on the surface of teeth because the adaptation to the dental arch is inadequate. Moreover, the control of force with these mouths gags is difficult, and patients avoid the practice of opening the mouth, in particular, the use of excessive force causes pain in the TMJ and muscles, such as the masseter and temporalis. It was exceedingly difficult for the patient to move the mandible laterally with the hand. The posterior bite plane, which was a modification of the functional appliance for anterior crossbite correction, was convenient and useful for improving the lateral movement of the mandible. This appliance could also be used at home, as a mouth gag with an expansion screw. The force applied by the expansion screw and the posterior bite plane was moderate, and gentle compared to that of the mouth gags currently in use. Therefore, the patient was not anxious about mouth opening exercises. The expansion screw was chosen from the "Leone Expansor Series Screws-Acrylic". We can use any size, 8 mm/35, 9 mm/40 turns, 11 mm/50 turns, or 13 mm/60 turns. In this case, an 8 mm/35 turns expansion screw was used.

## Conclusion

Mouth gags using with an expansion screw are often used in cases of CPM. In the conservative treatment of the CPM, oral rehabilitation, especially training for mouth opening, is important to achieve good outcomes. It is no overstatement that rehabilitation after removal of intermaxillary fixation affects outcomes. It is well known that after orthopedic surgery, such as fracture of the legs, rehabilitation is an important therapy for good prognosis. Trismus caused by osteoarthritis of TMJ was treated using a mouth gas with expansion screw and posterior bite plane. These two appliances effectively increased mouth opening and relieving pain in the TMJ and were superior to traditional appliances.

## Conflict of Interest

The author declares that there are no conflicts of interest regarding in publication of this paper.

## References

1. Ferrazzo, K.L., et al. "CT images of a severe TMJ osteoarthritis and differential diagnosis with other joint disorders." *Case Rep Dent.* 2013(2013):242685.
2. Haridas, R.P. "The Heister mouth gag or 'speculum oris.'" *Anaesth Intensive Care.* 43(2015):40-46.
3. Nakajima, T., et al. "Screw-type mouth gag for prevention and treatment of postoperative jaw limitation by fibrous tissue." *J Oral Surg.* 38.1(1980):46-50.
4. Arakeri, G., & Brennan, P.A. "Using ferguson mouth gag to improve the visibility and surgical access in TMJ surgery." *Int J Oral Maxillofac Surg.* 40.9(2011):1004-1006.
5. Hoefert, S. "The evolution of mouth gags. Presentation of a new medicated denhart mouth gag." *J Maxillofac Oral Surg.* 12.4(2013):475-479.